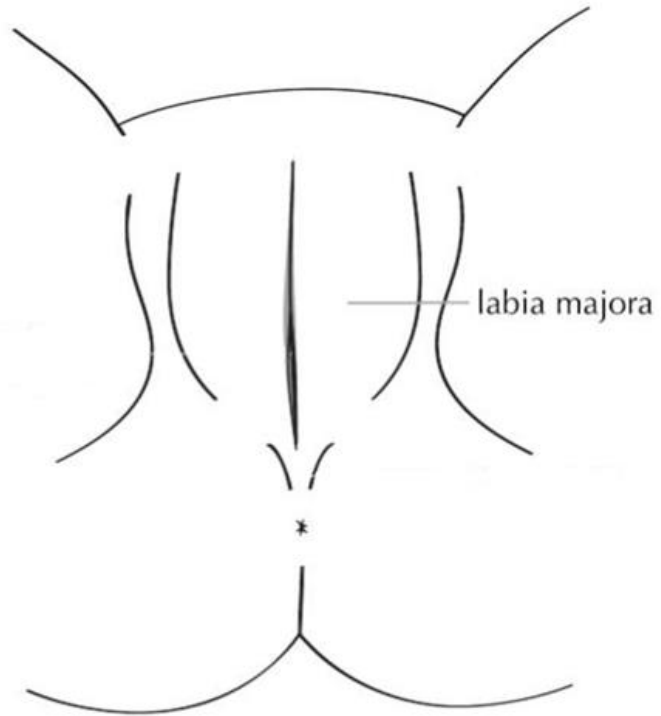


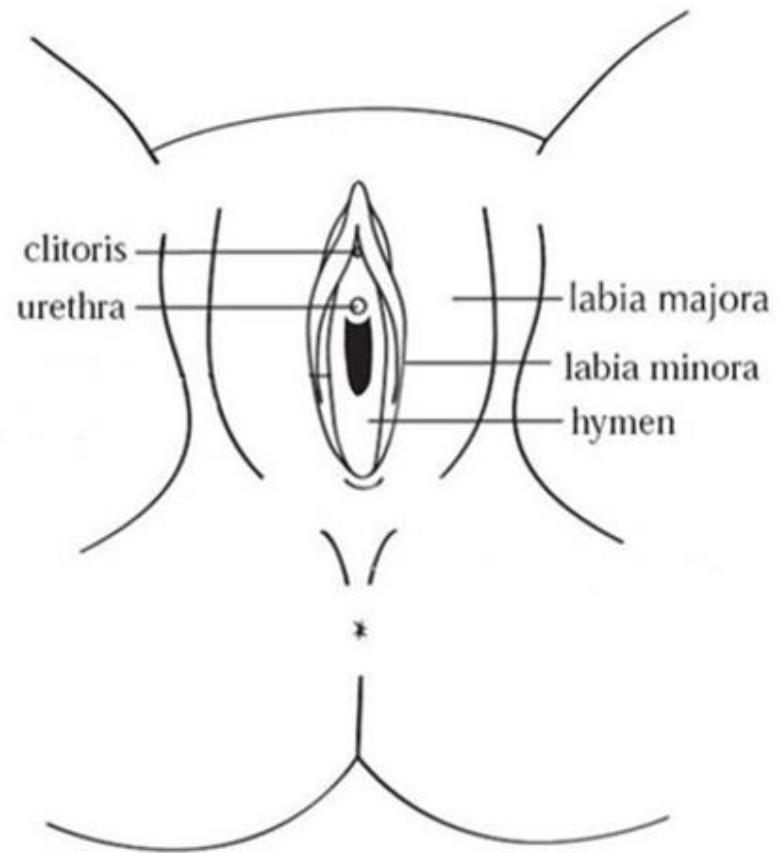
**A**

Pre Pubertal



**B**

## Prepubertal Open Crescentic



C

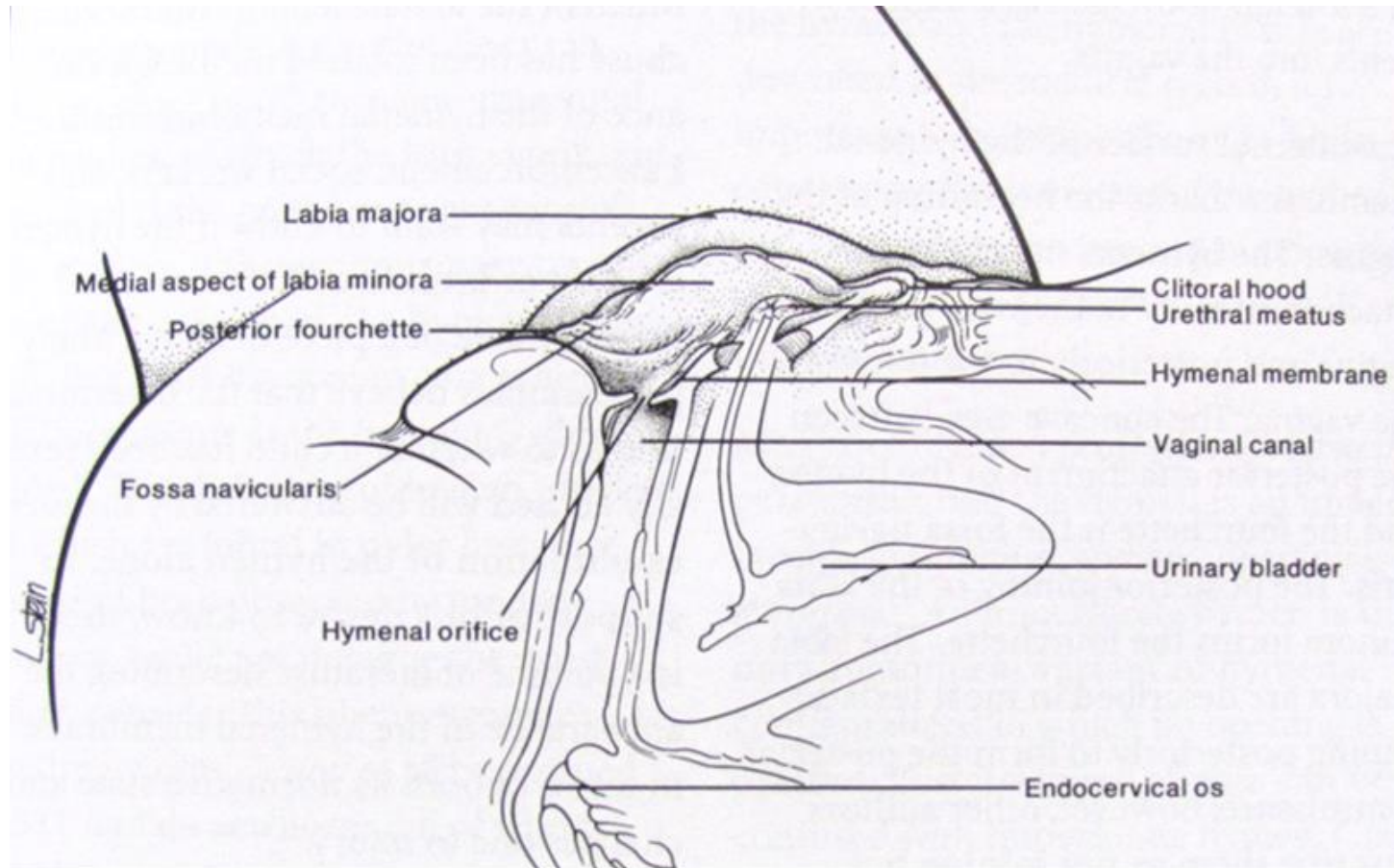


Figure 9.8. Cross-section of the female pelvis illustrating recessed position of the *hymenal* membrane at the entrance of the vaginal canal in Reece, Robert M (3<sup>rd</sup> ed). Child Abuse: Medical Diagnosis and Management. Philadelphia, AAP, 2009 (p289)